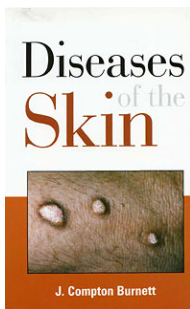


# James Compton Burnett Diseases of the Skin

Leseprobe

[Diseases of the Skin](#)

von [James Compton Burnett](#)



<http://www.narayana-verlag.de/b108>

Das Kopieren der Leseprobe ist nicht gestattet.

Narayana Verlag GmbH  
Blumenplatz 2  
D-79400 Kandern  
Tel. +49 7626 9749 700  
Fax +49 7626 9749 709

Email [info@narayana-verlag.de](mailto:info@narayana-verlag.de)

<http://www.narayana-verlag.de>

In unserer [Online-Buchhandlung](#) werden alle deutschen  
und englischen Homöopathie Bücher vorgestellt.



# DISEASES OF THE SKIN.

## PART I.

### Angina Pectoris from Suppressed Skin Disease.

ONE Sunday morning, some ten years ago, a gentleman ushered his wife into my consulting-room because she had been taken with an attack of *angina pectoris* in the street, on her way to church. Though only a little over thirty years of age, if so much, she had been subject to these attacks of

whole health-story from her earliest childhood. She said she was getting to the end of her teens, and was preparing to come out, but she had some cracks in the ends of her arms that were very unsightly; these cracks in her skin had troubled her from her earliest childhood. Erasmus Wilson was consulted •, he gave her an ointment which very soon cured her skin, and the patient came out socially, made a hit right off, and got married in due course. She had always felt very grateful to Erasmus Wilson for curing her arms, for otherwise, "How could I have appeared in short sleeves."

But there soon, followed dyspepsia, flatulence, dyspnoea, and pain

He called a year later with catarrhal symptoms of chest,

R *Rep.*

And twice subsequently the same remedy was repeated. Discharged quite cured in the fall of 1896.

Alopecia Areata in a Lady of  
35 Years of Age.

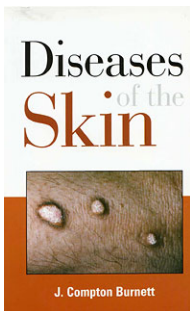
A married lady, 35 years of age, mother of three children, was brought by her husband to see me in the spring of 1897, for certain nerve symptoms, and, . . . "I have a bald patch on my head, about the size of a shilling, also two small wens on the left side of my head, in the hair."

was discharged cured, and the cure holds good to date. Said I the other day to his daughter, "How's your father's moustache ?"

"Oh ! it's all right ; as good as ever, but much more grey ; poor dear papa, he *was* in a way about his moustache."

#### Case of Alopecia Areata.

A very tall lad, fifteen years of age, came under my observation in March 1893, to be treated for alopecia areata of moderate severity. "Large bald patches." There were scars in the right side of the neck, where glands had seemingly been excised •, some not very large indurated glands in both sides of the neck and in both groins. The young



James Compton Burnett

[Diseases of the Skin](#)

280 Seiten, paperback  
erschienen 2008



**bestellen**

Mehr Homöopathie Bücher auf  
[www.narayana-verlag.de](http://www.narayana-verlag.de)