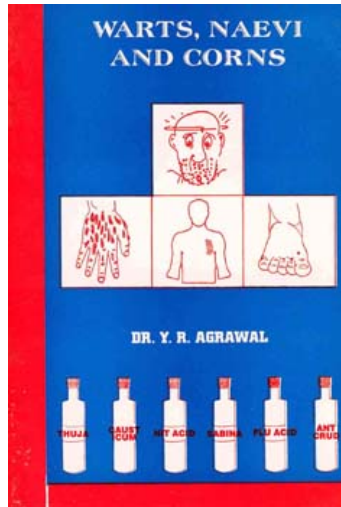


Y.R. Agrawal Warts, Naevi and Corns

Leseprobe

[Warts, Naevi and Corns](#)

von [Y.R. Agrawal](#)



<http://www.narayana-verlag.de/b396>

Das Kopieren der Leseproben ist nicht gestattet.

Narayana Verlag GmbH

Blumenplatz 2

D-79400 Kandern

Tel. +49 7626 9749 700

Fax +49 7626 9749 709

Email info@narayana-verlag.de

<http://www.narayana-verlag.de>

In unserer [Online-Buchhandlung](#) werden alle deutschen und englischen Homöopathie Bücher vorgestellt.


Narayana Verlag

Warts

Warts are little raised tumours, sessile or pedunculated, hard, generally round, rugose or mammillated. They are made up of coherent and enlarged papillae, each containing loop of blood vessels, and more or less nerve tissue, specially at their base.

Wart is also defined as a benign, localised hypertrophy of the skin, more rarely of the mucous membrane. *Verruca* is Latin and *condyloma* the Greek word for wart.

Warts may be hereditary due to what is called the sycotic miasm, often generations back. There may be warts due to hormone deficiency and warts are also caused by old age. Some warts are of psychic origin and are resistant to medical treatment but can be cured by psychic means. Homoeopathy regards all warts as sycotic or venereal origin. The warts around genitals are often syphilitic but **may** also be due to friction.

Clinically warts are classified into seven groups, viz.,

Type of warts-	Appearance of warts	Site of appearance
1. Common warts (<i>Verruca vulgaris</i>)	Dome shaped, cauliflower like growth. Nodule like shape.	Mainly of the uncovered skin, hands, arms and knees etc.
2. Flat warts (<i>Verruca plana juvenilis</i>)	Small, flat, yellowish, brown papules in large number.	Face, dorsa of hands, forearms, legs etc.
3. Plantar warts (<i>Verruca plantaris</i>)	Thickened growth, light black but dot on surface of the area, size varies from a pea to three penny size.	Soles, palms, generally at pressure points.
4. Digitate warts (<i>Verruca digitata</i>)	Finger like, lobulated growth, flat, broad, with a carb like appearance.	Scalp, back or shoulders.
5. Filiform wart (<i>Verruca filiformis</i>)	Like a stout thread projecting from the skin.	Neck, eyelids, face and lip.
6. Seborrhoeic warts (<i>Verruca plana senilis</i>)	Rounded or oval- flat. In size from a pea to finger nail.	Back and shoulder, chest and about the waist.

of tongue, pediculous type of warts, soft vegetating, do not secrete or very rarely secrete, appear very soon, increase very slowly forming like small sac. Warts of Thuja are found on conjunctiva behind the ears, eye brows, eyelids, fingers or say on all parts of the body. The Thuja warts is a little sensitive, appears to be covered with a thin film, and bleeds from the slightest touch. Moist, red, offensive warts.

External Medicines

In general it is dangerous to meddle with warts locally especially with mushroom warts.—Dr. Clarke

Warts have a constitutional base. When warts are suppressed we get symptoms of constitutional remedies like Nitric acid, Mercurius, Staphisagria, Thuja.—Kent.

Warts may be painted locally with Thuja at night and in the morning. In case of warts on the hands Kali Mur 3x diluted in table spoonful of water may be applied locally. In case of common warts the medicine which is taken internally may be applied externally to the warts in a solution once a day.

Warts Colour

Black	Calc, Hekla.
Brown	Sep., Thuj.
Greyish brown	Conium
Dark	Sep., Thuj.
Red	Ars., Bell., Calc, Caust., Cun., Nat s., Thuj.
Red all over body	Nat s.
Red pointed on	Bov.
Red size of a been	Calc.
Red & angry looking	Ars.
Red circle around with	Caust.
Red streak with	Bell.
Skin coloured	Calc.
White	Lyc, Sars.

Warts Type

Cancerous: Hekla., Semp v t.

Chronic: Acet ac, Am c, Ant c, Ars., Aur m n., Bar c, Cinnab., Calcinata 3x., Ferr pic, Kali m., Mag s., Nit ac, Ph ac, Pic ac.

Incipient or recent: Nat c.

Mole or Naevi

A mole is defined as a pigmented, fleshy naevus (Latin *Naevous*), a mole or birth mark which is circumscribed new growth of the skin of congenital origin. These marks are capillary angiomas, vascular or erectile tumours, that are composed of blood vessels. They are usually confined to the integument, though occasionally extending into the subcutaneous tissue. If composed of arterioles they are of bright pin colour while if made upon of venules, they are darker even bluish in colour.

Naevi are seen as congenital marks or occur within the first few weeks of life. Where of trifling size may disappear spontaneously or become so thin as the child grows in size and leave practically no deformity. In other cases where they are large and cover several inches of area, they cause ugly deformities. The marks of spots on different parts of body of the child at birth indicate failure on the part of some of the secretory organ of the skin. According to Fisher they assume all sorts of shapes, as a result of maternal impressison during pregnancy they are assumed to take the shape of the object at which the mother becomes frightened or which made profound impression upon her mind.

Naevi materni are classified in three categories according to their gravity:

Moles: The most common of all and are harmless. These are attributed to some alteration in the structures of the rete mucosum.

Venus Aneurysms: Anastomosis of venus capillaries are dark red circumscribed stain and appear on one side of the face. These marks which appear to be simple dilations of the sub-cuticular capillary vessels may increase in extent till puberty and then remain stationary.

Aneurysm and Dilation of the arterial capillaries: These are most important of the naevi and are likely to enlarge in life specially when stimulated by external irritation. They form slightly elevated spots, with well defined margins and granular surface which consists of an erectile vascular tissue.

Lycopodium: Materni naevi. It modifies naevi.

Medorrhinum: Red naevi.

Nux Vomica: Materni, venous naevi.

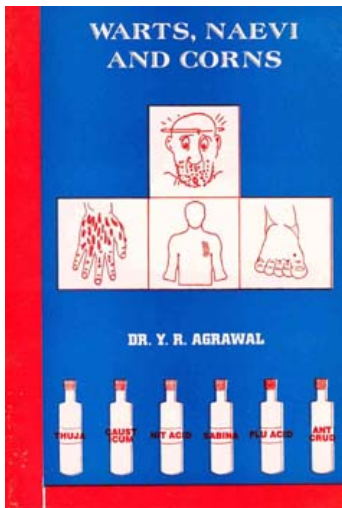
Radium Bromide: to be used in 30th potency in the treatment of naevi.

Preventive treatment for Naevi and Warts

The newly born child may not suffer from naevi or warts, the mother should be given Sulphur 30 followed by Thuja 30 and Merc Sol 30 once a week. Each medicine should be taken at least for one month.



Narayana Verlag



Y.R. Agrawal

[Warts, Naevi and Corns](#)

36 Seiten, Heft



bestellen

Mehr Homöopathie Bücher auf www.narayana-verlag.de